



EK PARIVARTAN FOUNDATION REGISTRATION NO: 130

EK PARIVARTAN FOUNDATION PAN NO: AAATE9879M

EK PARIVARTAN FOUNDATION 80G NO: AAATE9879MF20221

EK PARIVARTAN FOUNDATION NGO DARPAN : DL/2019/0230573

EK PARIVARTAN FOUNDATION GUIDESTAR INDIA : 11308

EK PARIVARTAN FOUNDATION CSR REG NO : CSR00040314

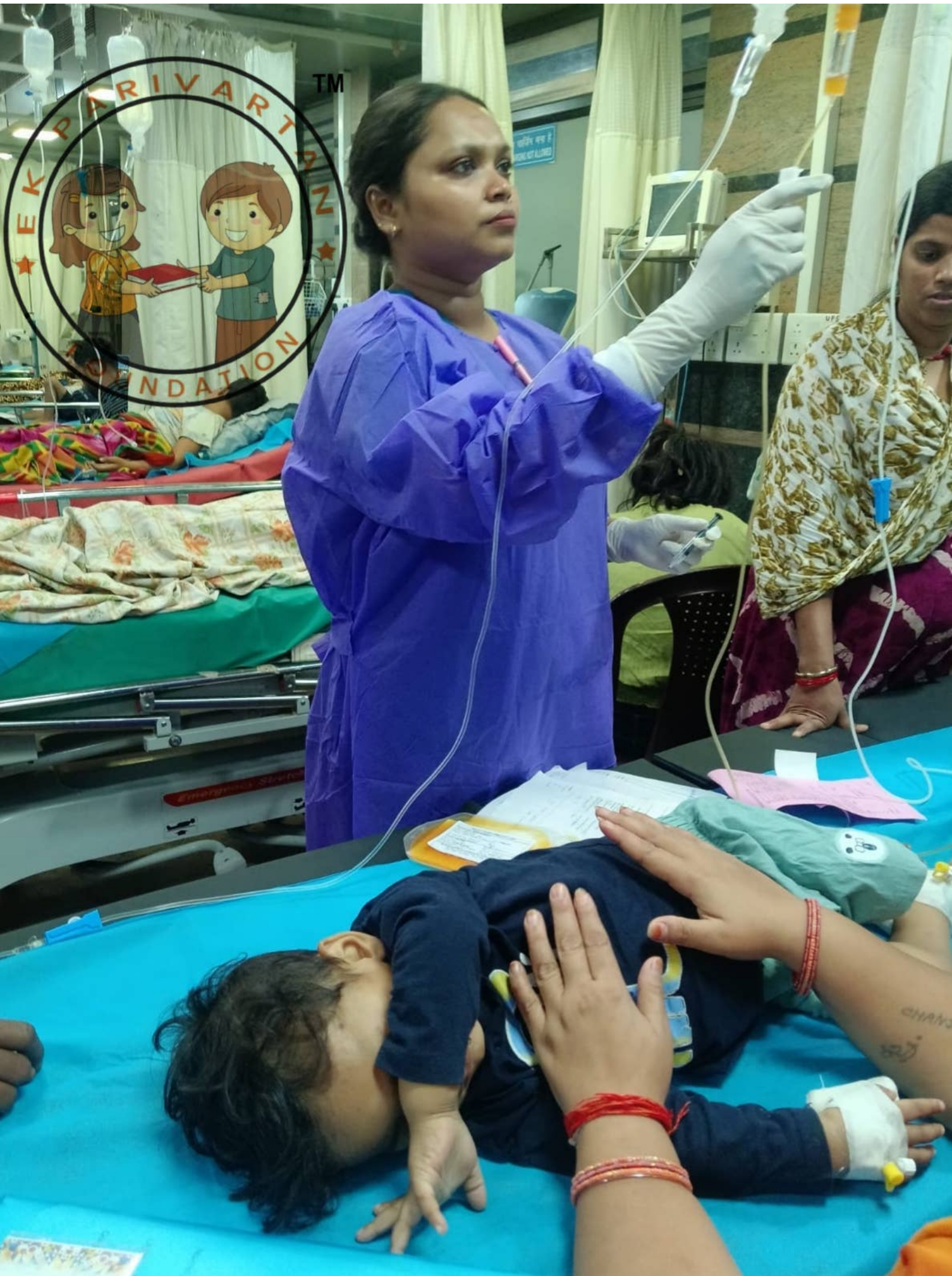EK PARIVARTAN FOUNDATION TM APP NO : 5822870

EK PARIVARTAN FOUNDATION MSME NO : DL-02-0040746

EK PARIVARTAN FOUNDATION WEBSITE : WWW.EPFNGO.ORG

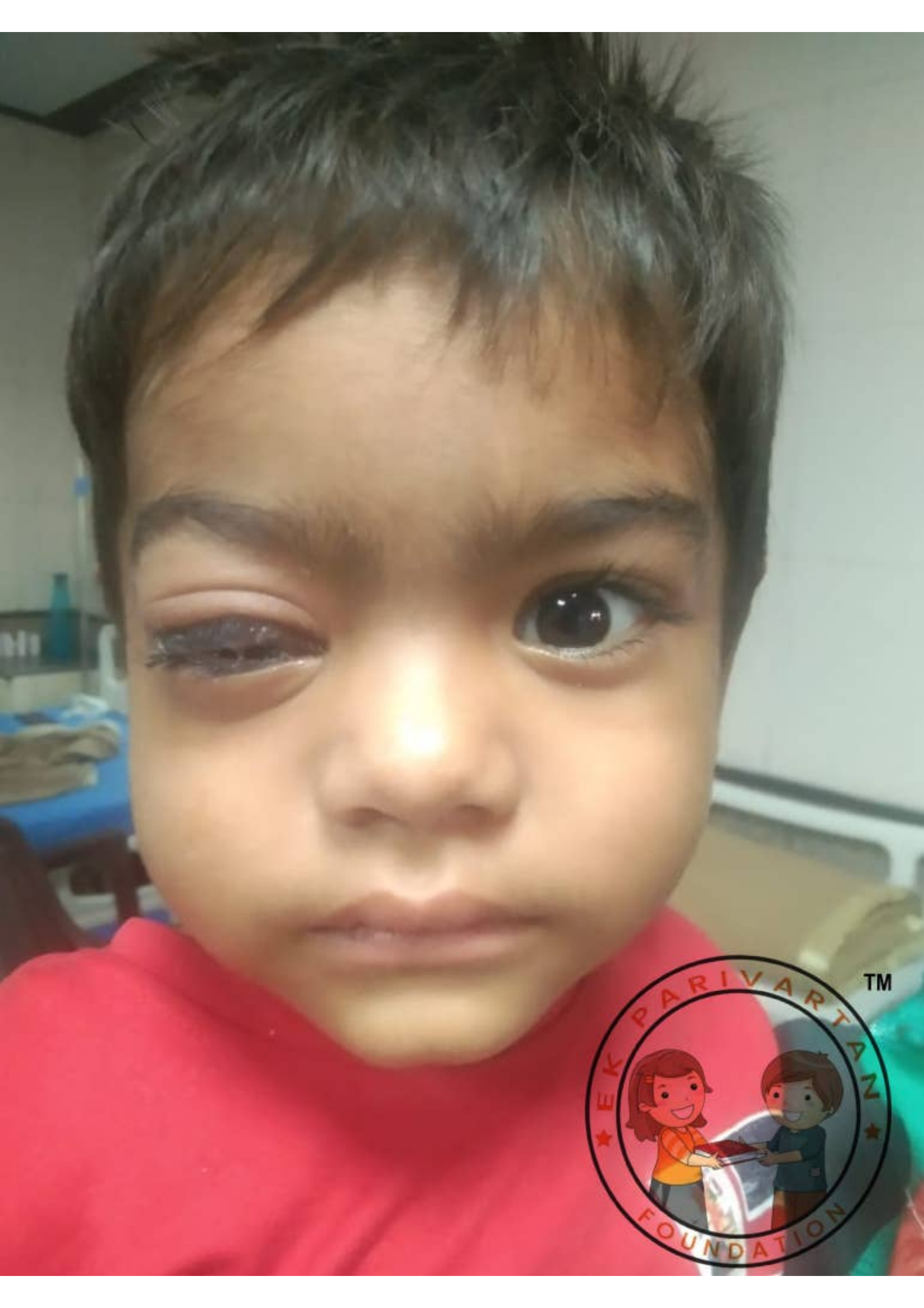EK PARIVARTAN FOUNDATION E-MAIL : INFO@EPFNGO.ORG

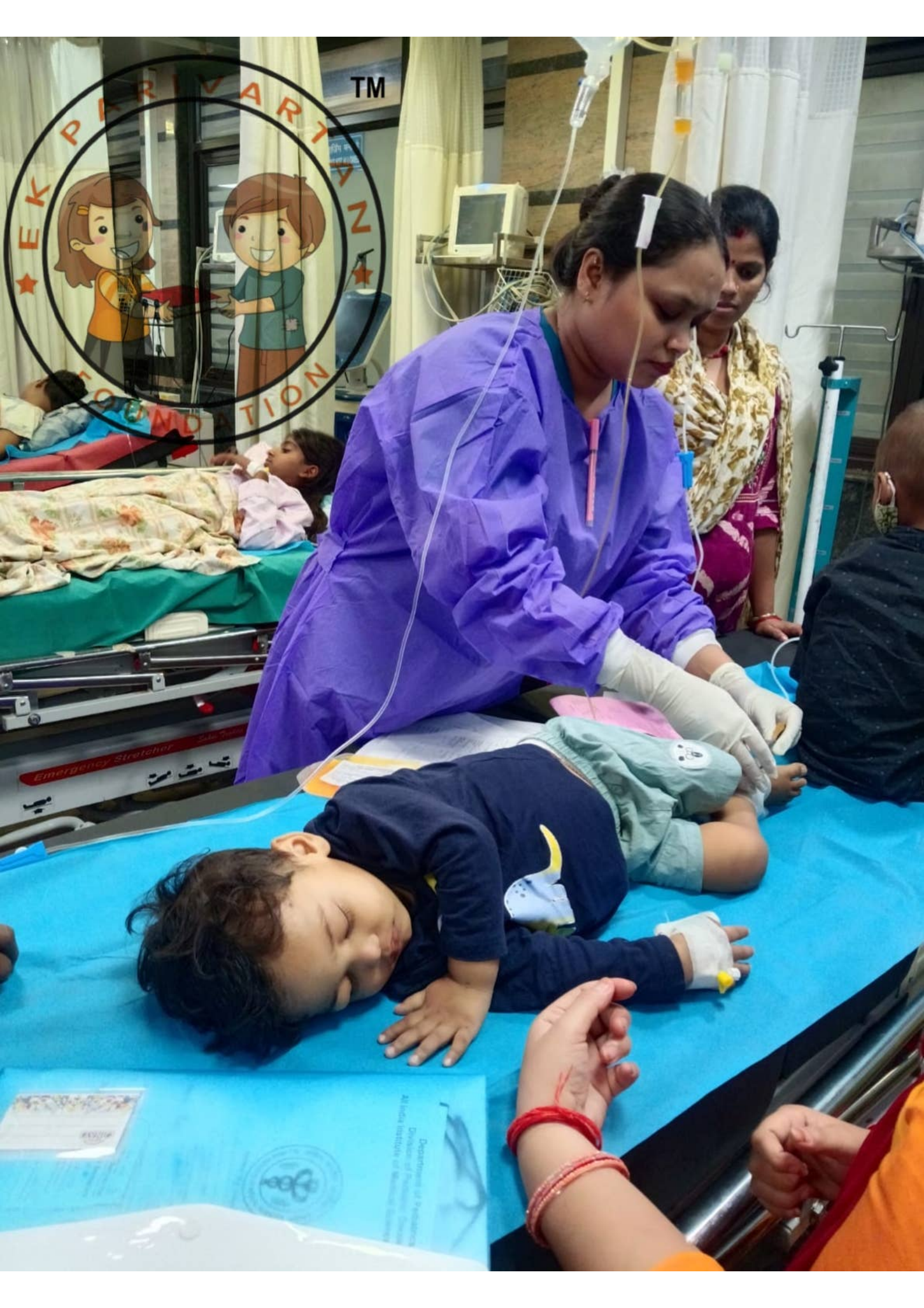PATIENT NAME	MASTER VIRAT
PATIENT FATHER NAME	MR. DEEPAK KUMAR
DOB AND GENDER	1.5 YR / MALE
DISEASE NAME	EYE TUMOR (RATINOBLASTOMA)
TREATMENT HOSPITAL	(AIIMS) ALL INDIA INSTITUTE OF MEDICAL SCIENCE
REGISTRATION NO	107760350
DEPARTMENT NAME	F-43, POC UNIT 1
TREATMENT COST	APPROX 1.5 LAKH
PATIENT FATHER OCCUPATION	LABOR
PATIENT ADDRESS	MEERUT UTTAR PRADESH



TM

EKA PARIVARTAN
FOUNDATION





TM

EKPRIVARTAZ
MEDICATION

Emergency Stretcher

Department of Pediatrics
All India Institute of Medical Sciences

10000000000000000000
10000000000000000000

Card



Section and Day VI
Wednesday & Saturday

Cabin No



Prof. Radhika Tandon's Unit

Name of the Patient	Sex/Date of Birth/S/D/W	Sex	Age	Address
Virat S/o Deepak		M	24	U P

8/5/25
 For IAC
 Screening for Govt. Scheme
 ABPMJAY - not eligible
 RAN/HMDG - BIS Postal No

18251993 187768358
 92581311 187768358

→ Ration card 5 member + 1
 → Annual Income Cert - Rs. 60000

विराट का कार्ड (VIRAT)

I.D. covered

Signature

Kindly keep this Card safe and bring it on your follow-up

- 1. धूम्रपान न करें (No Smoking)
- 2. Use Dustbin

10000000000000000000
 10000000000000000000
 10000000000000000000

डॉ. राजेन्द्र प्रसाद
O.P.D. Card

डॉ. राजेन्द्र प्रसाद
अ. भा. आयु. १
Dr Rajendra Pr
AIIMS, New
बु.एच.आई.सी.
UHID No.

रोगी का
Name of P

विभाग

दिनांक
DATE

निदान
DIAGNOSIS

उपचार Treatment

LOP

8/6/26

(27)

RAK OPD

CBC, LFT, RFT, ✓

PT/INR ✓

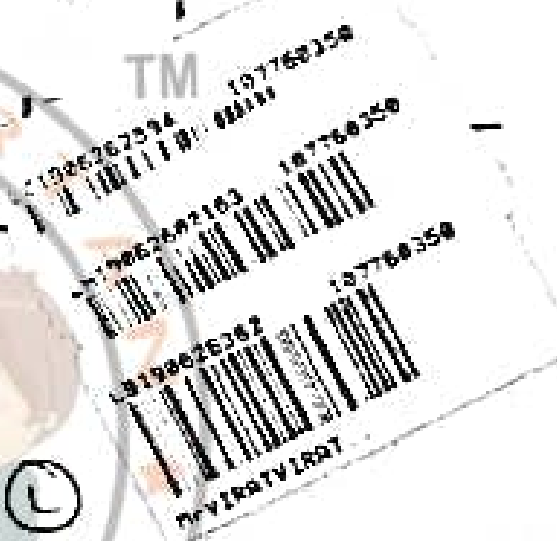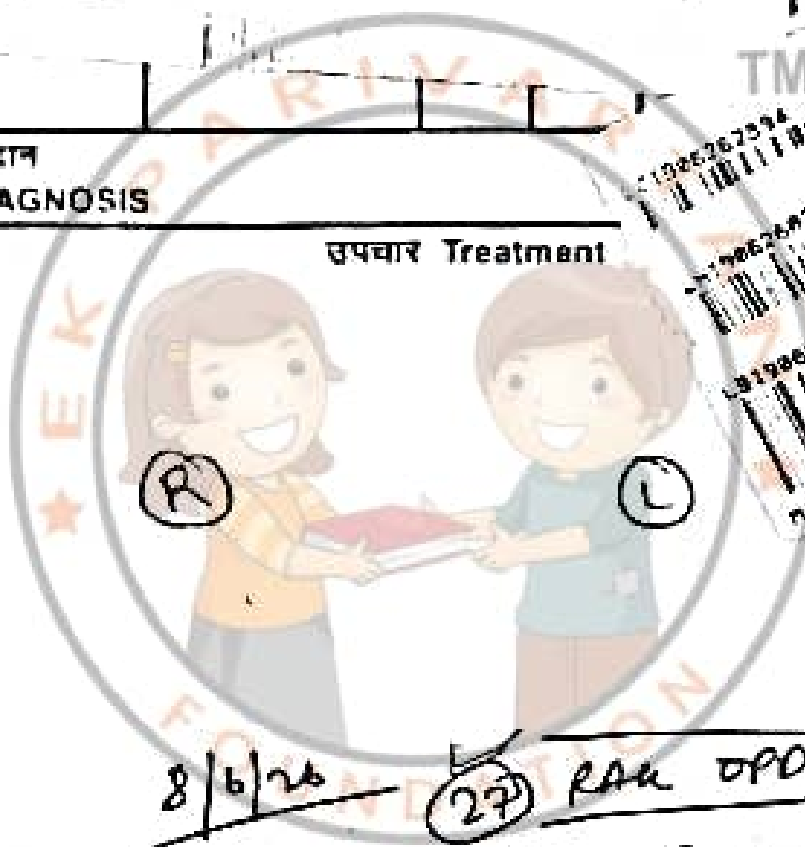
dep



अनुपम व दिन
Section and Day VI
शुक्रवार व शनिवार
Saturday

26B
कैबिन नंबर
Cabin No.

660/24



कृपया इस कार्ड को सुरक्षित रखें तथा अस्पताल में दिखाने के समय हर वक्त साथ लायें।

Kindly keep this Card safely and bring it on your follow-up visits.

1. धूम्रपान निषेध
2. कूड़ा कर्कट केवल कूड़ेदान में ही डालें
3. बूकिये नहीं

1. No Smoking

2. Use Dustbin

3. No Spitting



ओ मां ओ सं अस्पताल / A.I.I.M.S. HOSPITAL
 ललितम गेठी विभाग / Out Patient Department



एन सी आर विभाग

UHD 107786382

ESTABLISHED IN HOSPITAL FORMER



Dept No. 2024000000000000

OPR 4

VIRAT VIRAT

BIO DEEPAK
 27 2M 110 / 40 kg
 VILLAT ATERNA DELHI, INDIA

Age / Address

Age

Address

Follow Up Patient

Gender: M

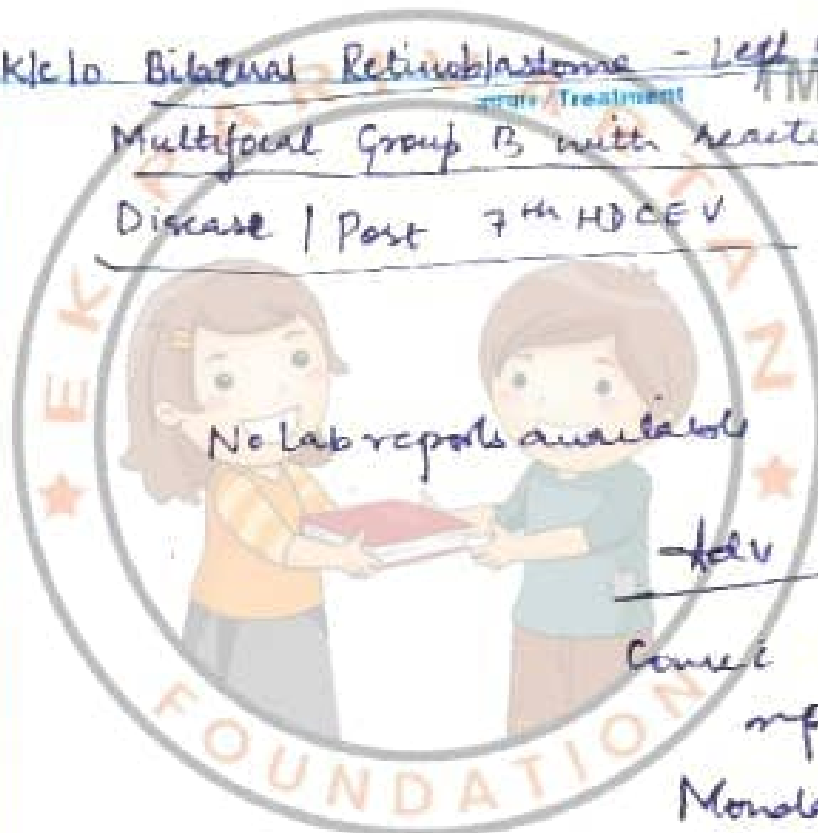
Present Diagnosis

Rate / Date

L15

12-10-24

~~KleLo Bilateral Retinoblastoma - Left Group V, Right
 Multifocal Group B with reactivation of B/L
 Disease / Post 7th HDCEV~~



No lab reports available

Consec CBC, LFT, RFT
 reports on

Monday Onco Clinic

CLEAN AND GREEN AIIMS / एम का पौी संकल्प, संकल्प में बादा बन

अपदान जीवन का बहुमूल्य उपहार / ORGAN DONATION - A GIFT OF LIFE

O.R.B.O., AIIMS, 26588360, 26593444, www.orbo.org Helpline - 1060 (24 hrs service)



(R) Enlarged Multifocal Grp B RB
 FIU/40 → (L) Reactivated Grp E RB with RD

Date:

05/05/2026

ASOCT

NRC Review ↓ SR Radiology

Initial MRI

Nov 2025

Current MRI

April 2026

Vt received → 60 HD-CGV

→ (L) 30 IAC (M+T)

→ (L) 1 Intra vitreal topotecan

PSOCT/OCTA

Nov 2025

April 2026

(L)

→ T2 Hypointense mass
FAF/FFA
Intra-ocular

→ No ev optic n/v invol

→ No ev extra-scleral
extension.

(L) → RD ⊕

→ T2 Hypointense

→ Near superior aspect
enhancing mass

ICGA

(R) → No mass appreciated

→ Not touching lens/CB

→ No ev optic n/v invol.

→ Post coats enhancement
But no definite extension
beyond scl

→ Possible choroidal invasion

Brain - WNL

USG

Apical Height

Basal Diameter

(R) → No mass appreciated

Brain → WNL

UBM


 Tannoy, LL

#7/PRC

→ FIU in RB Clinic (Wed) 2:00

(42-B) (6/5/2026)

For consultant opinion for

(L) Enucleation

EVA done ↓ unit 4

Date:

NEUROIMAGING

Dr. Kanni /
Dr. Sumit

CT

Right eye

Left eye

Dr. Shrushti /
Dr. Shifa

CG (Orbit)

Regressed mass

Mass red in size
= intralaminar Hghc

PK



MRI

(Tm) VENT

MRI (Brain) 06/01/20

second lesion

calciated mass

U/S/B Dr. Kanni

NRC Discussion:

(L2)

Mass has red in size with
intralaminar Hghc = RD ⊕ (localised)

Adv:

→ Repeat CE MRI Brain + orbit +

Qman optic N out

→ Axial
sagittal
coronal

(53)

→ NRC review: (Tm) loan

↓
later plan for Emulation

||

डा० राजेन्द्र प्रसाद नेत्र विज्ञान केंद्र
Dr. Rajendra Prasad Centre for Ophthalmic Sciences
A.I.I.M.S.
 Ansari Nagar, New Delhi-110029

11

Consultant Pratik Kumar Jais Sr. Resident P. S. Jais Jr. Resident Chauhan

CR No.	OPD No.	Sp. Clinic No.	Ward / Bed No.
			210
Age		Sex	Nationality
Family Income		Single / Married	
Permanent Address			
Local Address			
Tele No.			
Occupation			
D.O. Time			
D.O. Time			
Previous Admission / CR No.			
Admission-Routine / Emergency / EHS /			

DIAGNOSIS	Primary	2nd	3rd	Code No.
Right Eye Vd. follows light VSP - dip (R)	RE depressed multifocal Group B RB			1) No Sp 2) 3)
Left Eye does not Vd. follow light VSP - dip (L)	LE Reactivated Group E RB			1) 2) 3)

Medical / Operation Treatment

Result : Cured / Relieved / Stationary / Failure RT - 15kg

Photographs No. Histopath Report No.

X-Ray No.

3



UHID No: 187760350

DEPT. OF EMERGENCY MEDICINE

Emergency No: 022-2610010001

BOOK DATE: 16/01/2022

BOOK TIME: 02:15:18 PM

AGE SEX

MR. VIKAS VIBAT

2 years 2 months 16 days

M

RELIGION: HINDU, ETHNICITY: INDIAN, OCCUPATION: STUDENT, BIRTH DATE: 16/01/2019, BIRTH TIME: 02:15:18 PM, BIRTH PLACE: DELHI, PRESENTING COMPLAINT: [Blank], HISTORY OF PRESENT ILLNESS: [Blank], PAST MEDICAL HISTORY: [Blank], ALLERGIC HISTORY: [Blank], SOCIAL HISTORY: [Blank], FAMILY HISTORY: [Blank], PERSONAL HISTORY: [Blank], PHYSICAL EXAMINATION: [Blank], INVESTIGATIONS: [Blank], TREATMENT: [Blank], COMMENTS: [Blank]

Vitals: Resp: 24/min, HR: 122/min, BP: 100/60, SpO2: 99%, Temp: 99.6°F, RR: 24/min, S1: Normal, S2: Normal, S3: Normal, S4: Normal, Murmur: None, Crackles: None, Wheezes: None, Rales: None, Stridor: None, Cyanosis: None, Clubbing: None, Edema: None, Jaundice: None, Hematuria: None, Hemoptysis: None, Stool: Normal, Urine: Normal, GCS: E4V5M6, PUPILS: 3mm, REACTIONS: None, MOTOR: Normal, SENSORY: Normal, POSTURING: None, FLACCIDITY: None, SEIZURES: None, BLOOD SUGAR: 96 mg/dl, EXPOSURE: None, TEMPERATURE: 99.6°F, COLOUR: Normal, PALLOR: None, CYANOSIS: None, MOTTLED: None, ANY OTHER SKIN LESIONS: None

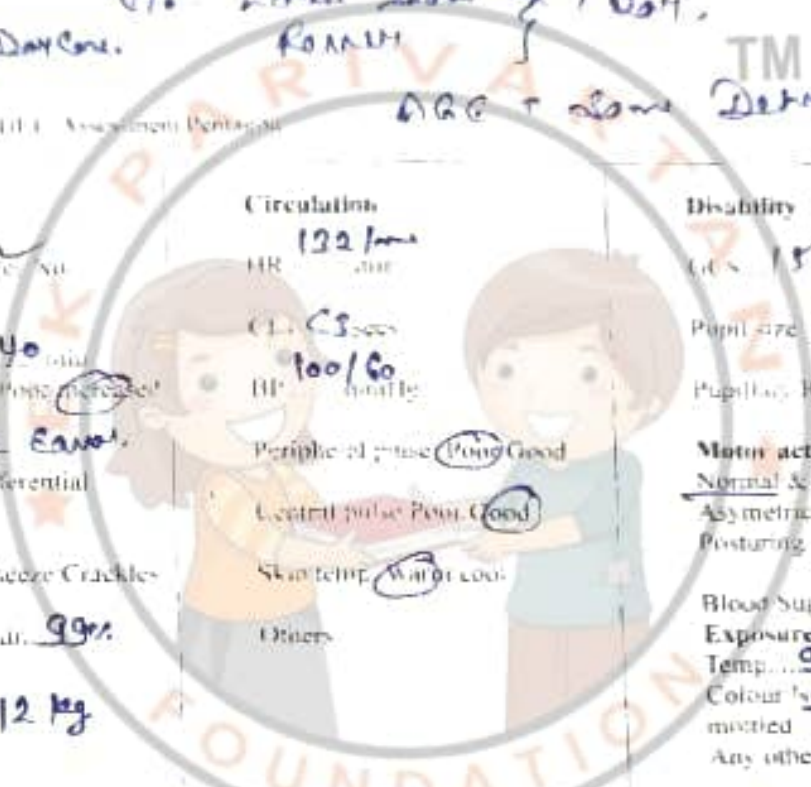Kala normal RB
 Post chemo

1st Low dose of 10mg
 RASH

Bobt from Day Care.

AGE + some Dehydration

Airway	Circulation	Disability
Open & stable ✓	HR 122/min	GCS 15
Breathing RR 24	CI 100/60	Pupil size 3 mm
Efforts Normal	BP 100/60	Pupillary Reactions None
Auscultation	Peripheral pulse (Poor) Good	Motor activity
Air entry: BIL Equal	Central pulse (Poor) Good	Normal & Symmetrical
Normal cost Differential	Skin temp: Warm cool	Asymmetrical
Added sounds	Others	Posturing Flaccidity Seizure
None Stridor Wheeze Crackles		Blood Sugar 96 mg/dl
SpO2 on Room air 99%		Exposure
WT - 12 kg		Temp 99.6°F
		Colour Normal pallor cyanosis mottled
		Any other skin lesions



Diagnosis

- Sno
- CBC / URG
- LFT / RFT
- CHEST XRAY
- Blood Cls
- Stool EIM
- ClS

3:30 PM
 16/12/20
 59
 ✓ IVR RL 30ml over 4 hrs. (75ml/kg)
 ↓
 ✓ IVR DNS + 100% KCl @ 40ml/hr.
 ✓ Bz. CEFTRIAZONE 600mg + 30ml NS over 30min IVX 12ml CAS
 ✓ Bz. PAN 15mg IV OD
 ✓ Bz. EMSEK 2mg IV SOS.

ब० रो० वि० कार्ड
O.P.D. Card



उपचार & दिन
Section and Day
गुरुवार & बुधवार
Monday & Thursday
IV

कमरा नंबर
Cabin No.

डा० राजेन्द्र प्रसाद नेत्र विज्ञान केंद्र
आ. भा. आयु. सं. नई दिल्ली 110029
Dr. Rajendra Prasad Centre for Ophthalmic Sciences
AIIMS, New Delhi 110029

यू.एच.आई.डी. संख्या
UHID No

आचार्य नमरा शर्मा का एकक
Prof. Namrata Sharma's Unit

रोगी का नाम Name of the Patient	पुत्र/पुत्री/महिला S/D/W	लिंग Sex	आयु Age	पता Address
------------------------------------	-----------------------------	-------------	------------	----------------

दिनांक DATE	निदान DIAGNOSIS
----------------	--------------------

उपचार Treatment

M/C/O (RE) Regressed Multifocal Crp. D RB
(LE) Regressing Crp. E RB
60 HDCEV Last - 11/3/25
30 IAC (M+T) ← 21/05/25
11/8/25
8/9/25

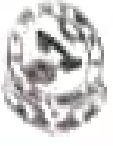EVA - 25/5/26

(LE) → ↑ Size of Mass & Intralaminar Hemm. & RB (localized)
- Plan for enucleation
Colored mass

कृपया इस कार्ड को सुरक्षित रखें तथा अस्पताल में दिखाने के समय हर वक्त साथ लायें।

Kindly keep this Card safely and bring it on your follow-up visits.

1. धूम्रपान निषेध
2. कूड़ा कर्कट केवल कूड़ेदान में ही डालें
3. थूकिये नहीं
1. No Smoking
2. Use Dustbin
3. No Spitting



Dr. Rajendra Prasad Centre for Ophthalmic Sciences
ALL INDIA INSTITUTE OF MEDICAL SCIENCES (AIIMS), New Delhi, 110029
Dr. Priyanka
Vitreous Report
CHANGE CERTIFICATE

UNED :	00790000	Cr. No. :	0-007900-20
Name :	MR VIRAT VIRAT	Department :	S. K. Centre (Eye Centre)
Age/Sex :	7 years 1 month 10 days / Male	Unit :	Unit IV
Ward Name :	OPC 2A	Bed No. :	228
Address :	VILLAGE: ATARRA, DELHI, INDIA	Drug Allergy, if any - ()	
Mobile No. :			
Date of Admission :	15/01/2020 01:10:23 PM		
Date of Discharge :	18/01/2020 08:10:00 AM		

ICD Code :	C38.2
ICD Description :	Malignant neoplasm retina

Diagnosis :	RE REGRESSED MULTIFOCAL DRP B RB LE REGRESSING DRP B RB WT II VITREOP- SEED
-------------	---

Investigation :	Systemic	NO SI	Ocular	VA BE FOLLOWS LIGHT IOP BE DIS NORMAL USG FOR PSE RE 1.2*2.7 MM LE 1.45*10.81 BE CALCIFIED MASSES NO RD
-----------------	----------	-------	--------	--

Treatment/Operative Procedure :	Surgeon	DR SUMIT / DR ANNEET	Surgery	BE EUA PLUS LE INTRAVITREAL TOPOTECAN 0.1 ML 50 MICROG TEMPORAL QUADRANT UNDER GA
	Date	18/01/2020		

Condition at Discharge :	Vision	BE FOLLOWS OBJECTS	IOP	BE LIG NORMAL
	Anterior Seg.	BE CORNEA CLEAR AC DEEP LENS CLEAR LE CONGESTION PRESENT	Posterior Seg.	BE L-OW PRESENT

Advice During Discharge :	Oral	TAB DIAMOX 1/2 TAB SO D/P EUA	Topical	.BE E/D HYGM TDS FOR 5 DAYS
	Follow Up	7 Feb 2020	Position	

7 Feb 2020
7:30 AM

NPO 6 hrs solids - 10 AM
4 hrs liquids - 4 AM

Anneet

Prepared By: Dr. Pooja Yadav Ophthalmologist

Signature Of Senior